

Where Connective Tissue, Fasciae, and Anatomy Meet in The Shoulder Girdle.

Aspects of Functional Anatomy.

This is the text of an oral presentation delivered at the 9th European Congress on Music Physiology and Performing Arts Medicine. Freiburg, Germany, April 2003

*Willie Fourie (Nat. Dip. Physiotherapy, Pretoria.)
Private Practice, Johannesburg, South Africa*

INTRODUCTION.

The only way to prevent any playing related injury in a musician is through a better understanding of our basic sciences, of which Anatomy is my own personal favorite.

Movement is **freedom**. My job is to restore movement and function to my patients and to give them back their freedom to the best of my ability. If you don't move well, you are either going to be eaten for supper, or you are going to sleep hungry. This law of nature also applies to musicians.

Studying Connective tissue and fasciae extensively during dissections over the past two years, my aim was to better understand the *interrelationship* of structures, and the role of fasciae in controlled movement of the upper extremity.

NEW MOVEMENT MODEL NECESSARY.

This entire muscle, bone, joint, ligament and neural tissue model is inadequate to explain the complexity of normal and pathological movement and function. A new model had to develop. This is slowly taking form as an understanding of the role played by connective tissue in movement is better understood. Connective tissue (CT) does not move bones or initiate movement, it merely controls the quality of the movement taking place.

The CT Bed provides connections between muscle layers as well as between adjacent muscles. Elasticity of the CT between structures is essential for an effective relationship between deep and superficial muscle layers.

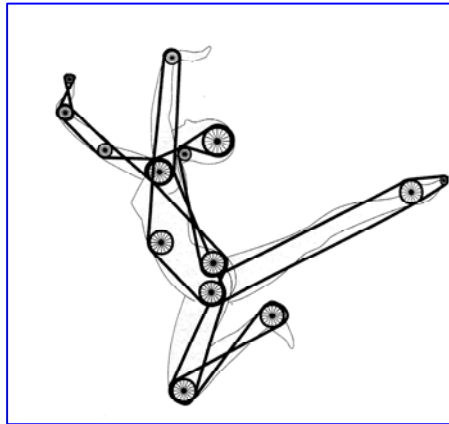
The potential for adhesions, thickening, and shortening is greatest in these CT interfaces, leading to poor quality of movement in the movement unit and ultimately to the development of pathology and pain.

MOVEMENT MODEL.

In order to make sense of what I saw in dissections, and to test this new understanding of the role of CT, I had to formulate a movement model. This further led me to start thinking in "movement planes" and to rather look at what is grouped together by fascial planes and sheets, rather than individual muscles and anatomical structures.

All movement in the human body is rotation around a movement axis in a joint or group of joints at all times. Pro- and supination; flexion/extension; abduction/adduction; internal/external rotation; name them, freedom to rotate around an axis is the basic feature of all movement.

It is not only the integrity of the joint that determines the quality of movement, all the soft tissue structures around a joint, and even a great distance away from the joint, will determine the quality of the movement and therefore the ultimate function of the unit.



This understanding led me to a more precise and individualised evaluation and treatment of potential upper extremity problems in musicians.

Structures in this model have to be free to slide and glide over each other. This is seen in synovial sheathes and bursae around structures. The availability of movement between structures, however, is much more widespread. Whole movement planes, or *functional bursae*, in the form of well defined fat pads between structures have to exist to allow freedom of movement and rotation around joints.

It is not only the integrity of the joint that determines the quality of movement, *all* the soft tissue structures around a joint, and even a great distance away from the joint, will determine the quality of the movement and therefore the ultimate function of the unit.

If the fascia of my abdominal wall is not free to move for example, even my glenohumeral joint could be under strain, and therefore ultimately the placement of my hand while playing a musical instrument.

MOVEMENT PLANES.

This layered system of myofascial compartments and planes are best seen in a cross section of the neck where the prevertebral fascia encircles the vertebral column and the deep spinal muscles to form a unit. Outside this, the investing layer of the deep fascia of the neck encircle the more superficial muscle groups to form a second muscle plane between its fascial sheets, enabling it to move independently from the deeper layer. Between the deep fascia and the skin we have yet another plane of movement with the freedom of movement provided by the adipose superficial fascia.

Anything interfering with the freedom of these three layers to glide on each other during movement of the head, will compromise the quality of neck (and even shoulder) movement and contribute to the development of pathology and pain in the movement apparatus of the neck – the facet joints or discs.

THE SHOULDER GIRDLE.

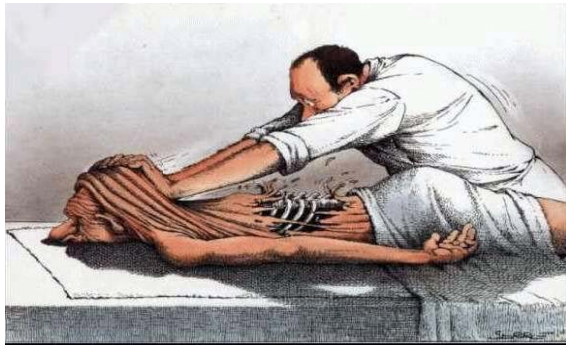
Extensive descriptions of the functional anatomy of the shoulder exist. I am not going to repeat that here and will only highlight a few aspects that I believe to be of clinical importance.

Because the shoulder is such a mobile structure, the balance within the joint structures can easily be upset by restrictions in soft tissue gliding – even well distant from the shoulder itself.

Looking at the shoulder with the above in mind, movement planes could be summarized as follows: -

THE SHOULDER MOVEMENT PLANES:

1st plane: The first plane of movement in the upper body is the movement between the skin (epidermis and dermis), the adipose superficial fascia and the deep fascia covering the first layer of muscles. This is the layer we can touch and has considerable freedom of movement. (Especially in the hands of **some** therapists!)



2nd plane: The second movement plane is between the superficial and deep muscles surrounding the scapula and shoulder. These **muscles** are the Trapezius, Lattisimus Dorsi, Deltoid, Pectoralis Major and Sternocleidomastoid. All the muscles with free edges to hold and manipulate between the fingers.



All their deep surfaces have well defined areolar tissue or adipose layers (fat pads) separating them from the deeper muscles, allowing gliding between layers.

3rd plane: The third movement plane includes the scapula, making the scapula almost a sesamoid bone within this movement plane. The muscles in this layer serve to stabilise the position of the scapula on the ribs and are more difficult to visualise as a layer. Muscles in this plane are the Rhomboids, Levator Scapula, Pectoralis Minor, Subclavius, Coracobrachialis, and Serratus Anterior.

Between all of these muscles and the ribs another well defined layer of loose areolar tissue exists, allowing considerable freedom for the scapula to slide over the ribs.

UPPER LIMB KINETIC CHAIN.

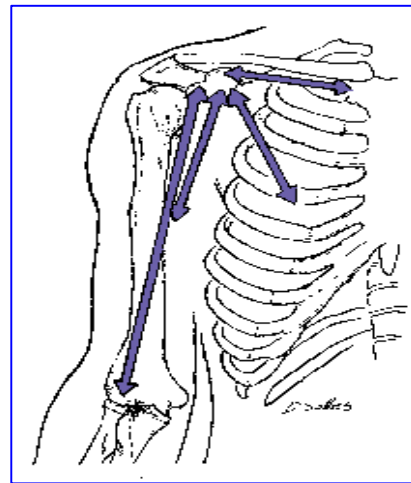
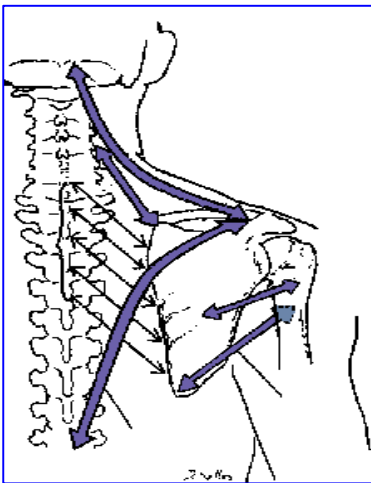
Movement in a limb takes place in a kinetic chain. The normal kinetic chain of the upper limb joints start at the sternoclavicular joint, then the acromioclavicular, glenohumeral, elbow, wrist and hand joints to complete the upper limb chain. Sometimes the scapulothoracic “joint” is included for completeness, (but not necessarily as part of the kinetic chain.)

It is an important “joint” though. During all movements of the upper extremity though, the placing of the hand and the controlled positioning of the scapula cannot be separated.

THE SCAPULA FUNCTIONALLY.

The scapula is largely a hanging or floating bone. Looking at the scapula functionally within its myofascial compartments, it is suspended from all sides.

- From the head, by way of the trapezius (and the sternocleidomastoid muscle to the clavicle indirectly).
- From the cervical spine by the levator scapula.
- From the thoracic spine by the rhomboids.
- From the upper arm by the teres major and minor.



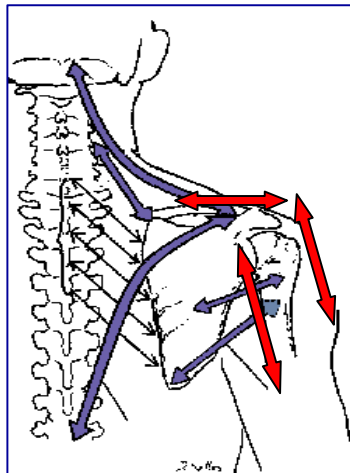
The elasticity of the CT of each of these muscles allows the shoulder girdle to float on top of the rib cage, guided by the attachments of structures through the coracoid process.

The coracoid process guides the movement of the scapula. These guides are the costocoracoid ligament (part of the clavipectoral fascia), pectoralis minor, coracobrachialis and the short head of biceps.

Because of all the structures attaching to the coracoid process, it can be described as a “hook” within the fascial web of the upper body with opposing structures pulling in different directions at this point. There are strong connections to the middle ribs, the radius and ulna of the forearm, to the humerus, and the middle clavicle.

THE ARM.

The arm, in turn is suspended from the scapula superficially by the deltoid muscle, and on a deeper movement plane level by the biceps brachii and coracobrachialis through the coracoid process anteriorly, and by the triceps long head from the infraglenoid lip of the scapula posteriorly.

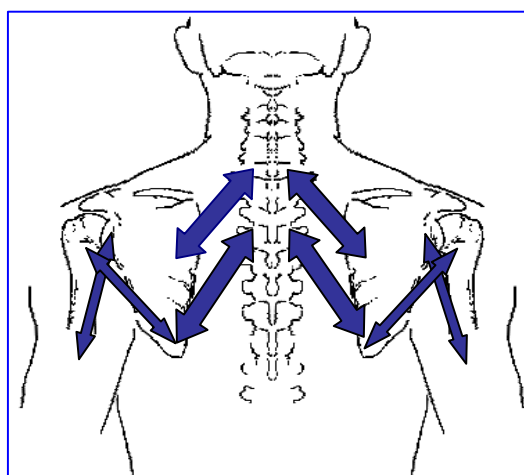


Tightness to any or all of these will result in a degree of immobilisation between the chest, the arm, and the scapula in the back, “fusing” the shoulder blade and interfering with scapulothoracic rhythm.

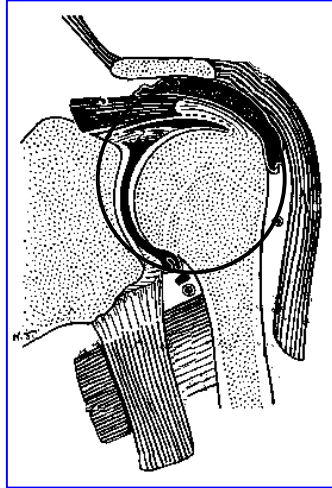
Virtually everything done with the upper limb involves the hand, but the hand is not used with the arm (elbow and shoulder) tight against the thoracic wall. Nearly every activity of the hand is preceded by slight abduction of the arm to “clear the elbow”. This position requires dynamic support – in other words, the major muscles supporting the joint are active. These muscles are those of the rotator cuff. As the force necessary to maintain dynamic stability increases, the deltoid and other muscles become increasingly active. During most activities, the rotator cuff muscles provide the majority of the dynamic stability (. They act as the compressors and steers of the glenohumeral joint during movement.

During more forceful use of the upper limb the big muscles of the back (latissimus dorsi) and the chest (pectoralis major) can generate considerable power. Through their attachments, and because of their powerful downward pull exerted on the humerus, they are also potential downward dislocators of the head of the humerus (Backhouse 1989). Supportive of synergistic muscles essentially maintains the integrity of the glenohumeral joint against this potential dislocating force. In this case the two forgotten muscles of functional anatomy of the shoulder come into play. The long head of triceps fulfils this synergistic role in opposing the downward pull of latissimus dorsi posteriorly . It is a very weak adductor extensor, but a very strong relocater of the arm. Anteriorly the coracobrachialis muscle fulfils the role of synergist, which is a weak flexor adductor, but a strong relocater of the arm.

A schematic picture of some of the features of shoulder functional anatomy may look something like this:



The “concertina” formed by the rhomboids, teres major and triceps muscles have to stay balanced during activity in order to protect the glenohumeral joint. Tightness in the teres/triceps crossover changes the kinematics of rolling and gliding in the glenohumeral articulation leading to irritation within the subacromial space due to excessive superior rolling of the head of the humerus in the glenoid fossa.



CONCLUSION.

For the musician, quality of hand movement is directly dependent on the stability and control of the scapulothoracic and glenohumeral joints and its surrounding soft tissue structures. Understanding this mechanism aids evaluation, treatment and prevention of upper extremity injuries in musicians

WILLIE FOURIE.

Freiburg, Germany, April 5, 2003