

Vastus medialis longus (VML) and vastus medialis obliquus (VMO) as part of the quadriceps femoris: Anything new?

W J Fourie. Private Practice. Roodepoort South Africa.

Introduction

The longstanding debate around vastus medialis (VM) muscle and its role in patellar alignment is still raging after several decades. Generations of clinicians have been saturated with the concept that knee rehabilitation requires an emphasis on vastus medialis obliquus (VMO) strengthening. Some of the early classic works included well thought-out observations that were unfortunately interpreted in a manner that has led to long lasting misinformation surrounding the extensor mechanism of the knee (Malone et al 2002).

The primary function of the quadriceps muscle is for providing large forces during pushing/pulling movements, as well as assisting in leg extension and shock absorption during running and jumping. Because of variable human activity patterns, the quadriceps muscle may require different patterns of force generation and force generating capacities. Activities may range from squatting, where force generation over large length ranges are needed, to jumping and running where the knee extensors must be capable of producing relatively large muscle forces at high shortening speeds (Blazevich et al 2006). To this end, the quadriceps must form a well coordinated unit. Although the quadriceps is recognised as the major extensor of the knee, the role of its individual parts is still incompletely understood and too often seen in isolation.

One interesting example is from a textbook "Injuries of the knee joint": *"The extensor apparatus may be regarded as consisting of two components, the rectus femoris, vastus lateralis and vastus intermedius, which extend the knee to within 10-15 degrees of full extension, and the vastus medialis which is selective in action and comes into force in producing the last 10-15 degrees of extension, although it may be used throughout the whole range in overcoming marked resistance"* (Smillie 1962). He further labelled the vastus medialis as "the key to the knee" and advocated that vastus medialis is "almost entirely responsible for the stabilization and protection of the joint from injury" (quoted in Malone et al 2002).

Continuing from the above, Lieb and Perry elaborated on "the key to the knee" in their anatomic and mechanical analysis of the extensor apparatus (Lieb & Perry 1968). They ascribed some of their observations to the orientation of longitudinal and oblique fibres in the VM, the independent innervation of the VMO fibres and the function of the oblique fibres to align the patella in the last 10 -15 degrees of extension. Since 1968, many clinicians have quoted the Lieb and Perry paper as being supportive of selective recruitment and exercise in quadriceps function. The term "VMO strengthening" and its emphasis has

become synonymous with patellofemoral exercise prescription (Malone et al 2002) in particular and in post surgical strengthening exercises in general.

Whether the VM is a single anatomical structure or made up of two distinct muscles, the VMO and the VML, or whether this would support or refute its role in muscular control of the patella forms the basis for excellent reviews by Smith et al (2009) and Malone et al (2002). On one side of the debate, anatomists and surgeons refer to a number of factors distinguishing the VM as being two independent muscles because of the observed change in fibre alignment angles along the VM to the patella and patellar aponeurosis that may produce two distinct lines of action (Lieb & Perry 1968; Weinstabl et al 1989), the presence of a fascial plane dividing the VMO and the VML (Lieb & Perry 1968; Javadpour et al 1991), and a specific innervation to the VML and VMO muscles theoretically allowing the VML and VMO to exhibit different contraction onset timings (Lieb and Perry 1971).

From the above it has been hypothesised that the VMO and VML are separate muscles. The fact that muscles with different anatomical architecture show different functional roles (Blazevich et al 2006) is referred to support for this view. As a result, it is assumed that the VMO act more as a stabiliser to lateral patellar pull, while the VML contribute more to knee extension with the other vastii (Speakman & Weisberg 1977). For this reason the retraining and strengthening of the VMO is regarded to be important in the management of anterior knee pain and patellar instability (McConnell 2002).

On the other end of the spectrum, observers have suggested that these muscles should be considered as a single anatomical structure (Nozic et al 1997) and further that if the VML and VMO are positioned in series, any force developed by the proximal VML must be transmitted to the distal VMO. This questions the notion that the VMO and VML can be independent muscles and may account for why electromyographic (EMG) studies are unable to show a substantial isolated contraction of the VMO from the VML (Rainoldi et al 2008). It has further been observed that the innervation of VMO by branches of the femoral nerve is inconsistent and the presence of a fibrofascial plane is an anatomical exception (Peeler et al 2005; Barbaix & Pouders 2006). The balance of the debate is towards the latter view of VM being a single muscle (Smith et al 2009).

On the functional level literature does not support that isolated VMO exercises exist with both VMO and VL being highly active in terminal range of extension together with the other heads of the quadriceps. Literature supports the concept of significant muscle inhibition being present during pain and effusion, while patellar taping and bracing reduces perceived pain and thereby improves quadriceps output (Malone et al 2002). There is however limited support that taping or bracing influences patellar alignment (Powers 2000).

Virtually all pictures, drawings or dissection images of the knee extensor mechanism portray its muscular, tendinous and ligamentous components commonly without surrounding deep

fascia (fascia lata), myofascia or fat pads. In textbooks of anatomy, the fascia lata is mostly described separately and often receives only a few descriptive lines (e.g. Moore and Dalley 2006), while fascia's biomechanical role is usually limited merely to containment (Jones, 1944).

In order to improve understanding of the extensor mechanism as a functional unit, a study was undertaken to investigate the fascia lata in its relationships to the underlying quadriceps muscles in the distal half of the thigh.

Materials and methods

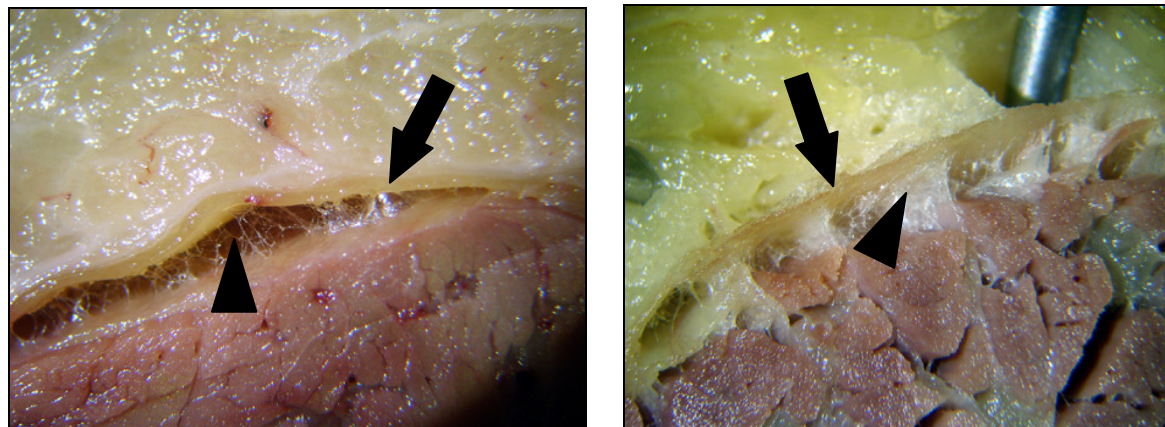
10 thighs from 5 preserved cadavers (2 male and 3 female) between the ages of 70 and 85 years at the School of Anatomical Sciences of the Faculty of Medicine at the University of the Witwatersrand, Johannesburg, South Africa were dissected. Three of the cadavers were of average body weight, while two (both female) could be classified obese. Using macrodissection techniques, layered dissections of the thigh were done from dermis to muscle. After carefully reflected the skin, the superficial fascia (subcutaneous layer or hypodermis) was inspected and removed in layers to fully expose the deep fascia of the thigh (fascia lata). Finally, the fascia lata was carefully removed in sections and from individual muscles while observing and documenting fascia/muscle relationships. Care was taken not to damage underlying muscles by excessive traction on the fascia. The ease with which fascia and muscle could be separated from each other was noted. Should damage to the muscle be observed, the fascia was removed further by sharp dissection with a scalpel.

Results

The deep fascia or fascia lata of the thigh.

The deep fascia (fascia lata) appeared as a whitish, strong laminar sheet of connective tissue covering the extensor muscles. Medially, predominantly over the adductor and the vastus medialis muscles, the fascia lata is thin and almost transparent. It is well developed, thick and tough anterolaterally. The lateral thickened part it is commonly called the tractus iliotibialis or iliotibial band stretching from iliac crest to tibial tuberosity.

Two different relationships between the fascia lata and underlying muscles were observed. In some areas fascia was easily separable from underlying muscles and was therefore described as a **loose relationship (LR)** between fascia and muscle (figure 2A). In these areas the fascia lata could be lifted off underlying muscles without potential damage to the underlying muscles. In other areas the fascia adhered firmly to underlying muscles, forming a **close or epimysial relationship (CR)** between fascia and muscle. This was due to a series of intramuscular septa that branch off the deep surface of the fascia between muscle fascicles (figure 2B). In these areas sharp dissection was needed to minimise muscle fascicle damage or disruption.



A

B

Figure 1. The relationships between the fascia lata and underlying muscles in the anterior thigh. A. Loose areolar connective tissue (black arrowhead) between fascia (black arrow) and muscle in a **loose relationship**. **B.** A **close relationship** between fascia (black arrow) and muscle with intramuscular septa (black arrowhead) passing from fascia between muscle fascicles.

Muscular relationships to the fascia lata

The deep fascia could easily be removed from the entire surface of the rectus femoris (RF) muscle by blunt dissection. Varying amounts of loose areolar and adipose tissue was consistently present between the fascia lata and muscle epimysium. The adipose layer in the muscle's upper third appears particularly prominent (fig 2 –arrowhead).

In all dissections the fascia lata could easily be separated from the entire vastus lateralis (VL) by blunt dissection (fig. 3). A **loose relationship** existed between fascia and muscle epimysium throughout created by varying amounts of loose areolar and adipose tissue. In the more adipose cadaver specimens the separating layer had the appearance of a distinct extra layer of fascia between the fascia lata and muscle. The lateral part of the fascia was considerably thicker than the rest of the entire fascia lata.

The fascia lata covering VM appeared thin and almost transparent in all cases. In all the specimens, combinations of a **loose relationship AND close relationship** between fascia lata and muscle were found. Areas of loose relationships bordered onto the RF and became wider distally (fig.4). The rest of the VM was closely associated with the fascia lata by intramuscular septa passing from the deep surface of the fascia between muscle fascicles (fig. 5). The surface area of close relationships between muscle and fascia therefore showed variations between specimens. In all the areas of close relationships, removal of the fascia lata from underlying muscle by blunt dissection pulling on the fascia as done for VL and RF resulted in damage to the underlying muscle fascicles (fig. 5). For removal of the fascia lata with minimal damage to fascia and/or muscle, sharp dissection needed to be used in the regions of close relationship.

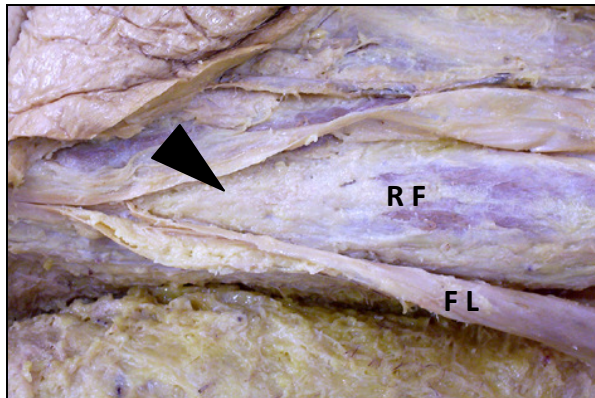


Figure 2. Fascia lata (F L) easily lifted off rectus femoris (R F). Adipose tissue is collected in the upper third of the muscle between fascia and muscle (arrowhead).




Figure 3. Fascia lata easily separated from VL

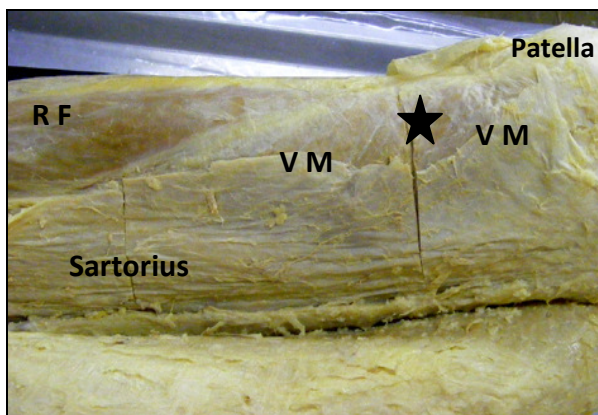


Figure 4. VM. An area of loose relationship where the loose fascia lata has been cut away (black star).

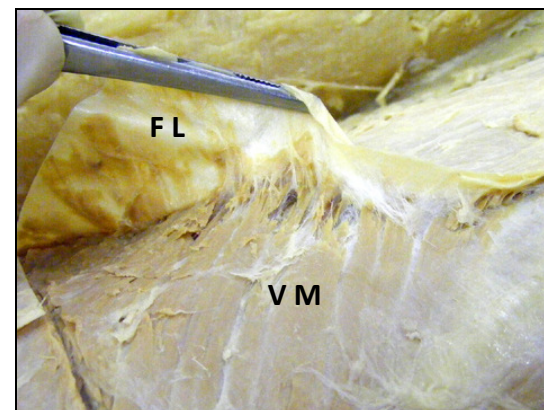


Figure 5. Damage created in the V M by excessive pull on the fascia lata.

Additional fascial and connective tissue relationships

RF could by blunt dissection be separated from the underlying vastii (fig. 6). These muscles each have their own epimysium with a layer of loose areolar and adipose tissue between RF and vastii from origin to insertion. VL has a close epimysial relationship with the lateral intermuscular septum with fascial septa passing from the fascia between muscle fascicles of the muscle. Just above the knee, the deep surface of the fascia lata/ITB is firmly attached to the lateral femoral condyle (Fig 7).

The oblique part of VM attaches strongly to the tendon and fascia of adductor magnus. Superior to the adductor miatus, VM continues fascial relationship with the adductor canal and its neurovascular contents. Medially, the fascia/epimysium of VM splits to invest sartorius, and then continues as the fascia over the adductors and gracilis.

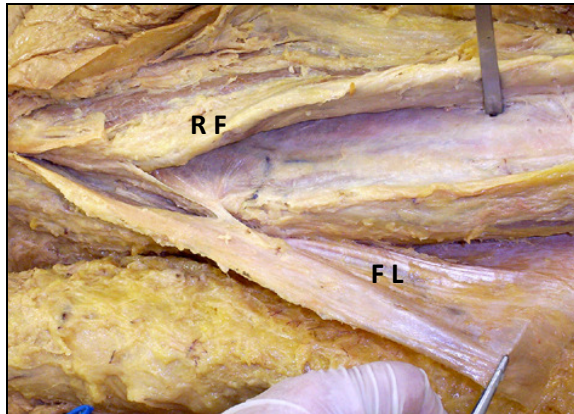


Figure 6. R F lifted off the vastii. Note the smooth deep surface.

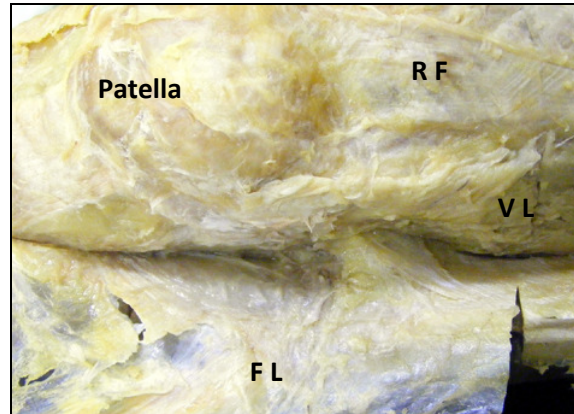


Figure 7. The deep surface of the fascia lata is firmly attached to the lateral femoral condyle.

Discussion

Like muscle and bone, fascia is an adaptation of structure and function. In maintaining an upright posture, the human musculoskeletal system has to alternate between a rigid column for stability and passive support, and a mobile unit for locomotion and movement. Muscles adapt to this dual role by gaining wide insertions to ensheathing membranes and fasciae, as well as its deeper septa and partitions (Jones, 1944; Stecco et al., 2006). This is particularly true in the lower limb.

By muscles gaining widespread and unprecise, but powerful attachments to large areas of the limb as a whole rather than to its individual moving parts, the extensive fascial sheets provide a functional homologue of an ecto-skeleton for the limb (Jones, 1944), a flexible skeleton onto which muscle fibres are anchored with the purpose of distributing and directing muscular forces within the locomotor system. This fascial skeleton is maintained at a basal tension the muscles inserting into it, and that when these muscles contract, they transmit part of their traction forces to the fascia sometimes influencing body-wide responses (Myers, 2009; Stecco, 2004).

When viewing the fascia lata as part of an entire deep fascial “ectoskeleton” forming part of a weight-supporting column, areas of close epimysial relationships (as seen in VM), and areas of enhanced fascia-on-muscle gliding (seen in RF and VL) changes the general view of

the fascia lata being purely a stocking for containment and circulatory support. The attachment of seemingly diverse muscles to a common fascia means that fascia is in a strategic position to co-ordinate muscle activity into a myofascial unit for knee extension rather than considering the quadriceps femoris muscles as the extensors of the knee. From the above observations it also becomes evident that the force generated by the four heads of the quadriceps is transmitted not only directly to the patella, but also to connective tissue elements inside and outside the entire knee complex.

With muscles of the thigh gaining wider attachment to the fascial ectoskeleton (Jones, 1944) and force transmission being spread to adjoining fascial structures (Huijing, 2009), it could be suggested that the additional close fascial relationships observed in vastus medialis forms part of a myofascial force transmission system working to stiffen the fascial ectoskeleton and thus augment its function. The contributions of the gluteus maximus and tensor fasciae latae muscles (also in close fascia/muscle relationships like VM) in stiffening the lateral fascia lata to enhance the force generation of the vastus lateralis muscle (Moore and Dalley 2006). The possible contribution of the fascial attachments of sartorius and vastus medialis into the fascia lata is not clear and open to speculation. It may well be that linking different muscles of the thigh together through the deep fascia promotes their contraction as a coordinated unit.

Summary.

The quadriceps muscles, fascia lata together with the tensor fasciae latae and sartorius muscles form a well integrated unit in the front of the thigh and lower limb as a whole. I am therefore of the opinion that they should be viewed as such in the planning and executing of treatment and rehabilitation.

References

- Barbaix E, Pouders C. 2005. Vastus medialis obliquus. Clin Anat;19:184
- Blazevich A J, Gill N D, Zhou S, 2006. Intra- and intermuscular variation in human quadriceps femoris architecture assessed *in vivo*. J Anat;209:289-319 DOI: 10.1111/j.1469-7580.2006.00619x
- Garfin S R, Tipton C M, Mubarak S J, Woo S L-Y, Hargens A R, Akeson W H, 1981. Role of fascia in maintenance of muscle tension and pressure. J Appl Physiol.:Respirat Environ Exercise Physiol; 51(2): 317-320

Huijing P A, 2009. Epimuscular myofascial force transmission: a historical review and implications for new research. International society of biomechanics Muybridge award lecture, Taipei, 2007. J Biomech; 42: 9-21 DOI: 10.1016/j.jbiomech.2008.09.027

Javadpour P J, Finigan P J, O'Brien M. 1991. The anatomy of the extensor mechanism and its clinical relevance. Clin J Sport Med 1;233-235

Jones F W, 1944. Structure and function as seen in the foot. The Williams & Wilkins Company, Baltimore

Lieb F.J, Perry J. 1968. Quadriceps function: an anatomic and mechanical study using amputated limbs. J Bone Joint Surg 50: 1535-1548: 1968

Lieb F.J, Perry J, 1971. Quadriceps function: An electromyographic study under isometric conditions. J Bone Joint Surg 53: 749-758:1971

Malone T, Davies G, Walsh W M. 2002. Muscular control of the patella. Clin Sports Med 21: 349-362

McConnell J. 2002. The physical therapist's approach to patellofemoral disorders. Clin Sports Med 21:363-387

Moore K L, Dalley A F, 2006. Clinically orientated anatomy. Fifth edition. Lippincott Williams & Wilkins, Philadelphia

Myers T W, 2009. Anatomy Trains (second edition). Churchill Livingstone, Edinburgh.

Nozic M, Mitchell J de Klerk D 1997. A comparison of the proximal and distal parts of the vastus medialis muscle. Aust J Physiother 43:277-281

Peeler J, Cooper J, Porter MM, Thliveris JA, Anderson JE. 2005. Structural parameters of the vastus medialis muscle. Clin Anat 18:281-289

Powers CM. 2000. Patellar kinematics, part1: the influence of vastus activity in subjects with and without patellofemoral pain. Phys Ther 80:956-964

Purslow P P. 2002. The structure and functional significance of variations in the connective tissue within muscle. Comp Biochem Physiol Part A; 133: 947-966

Rainoldi A, Falla D, Mellor K, Bennell K, Hodges P. 2008. Myoelectric manifestations of fatigue in vastus lateralis, medialis obliquus and medialis longus muscles. *J Electromyogr Kinesiol*

Smillie I S. 1962 *Injuries of the Knee Joint*. 3rd edition. Baltimore, M.D.: Williams and Wilkens

Smith T O, Nichols R, Harle D, Donell S T, 2009. Do the vastus medialis obliquus and vastus medialis longus really exist? A systemic review. *Clin Anat*;22: 183-199 DOI 10.1002/ca20737

Speakman HG, Weisberg J. 1977. The vastus medialis controversy. *Physiotherapy* 63:249-254

Stecco C, Porzionato A, Macchi V, Tiengo C, Parenti A, Aldegheri R, Delmas V, De Caro, R, 2006. *Ital J Anat Embriol*; 111(2): 105-110

Stecco L, 2004. *Fascial manipulation for musculoskeletal pain*. Piccin Nuova Libreria S.p.A., Padova

Toumi H, Poumarat G, Benjamin M, Best TM, F'Guyer S, Fairclough J. 2007. New insights into the function of the vastus medialis with clinical implications. *Med Sci Sports Exerc* 39: 1153-1159

Weinstable R, Scharf W, Firbas W. 1989. The extensor apparatus of the knee joint and its peripheral vasti: Anatomic investigation and clinical relevance. *Surg Radiol Anat* 11:17-22

W J Fourie ©

September 2010